

# Vertical malocclusions: etiology, development, diagnosis and some aspects of treatment

By Ib Leth Nielsen, DDS

**V**ertical malocclusions result from the interplay of many different etiological factors during the growth period. These factors include growth of the maxilla and mandible, function of the lips and tongue and dentoalveolar development with the eruption of the teeth. One particularly important factor in the development of deep bite and open bite is the pattern of growth of the mandible. Variations in the rate of growth in both the maxillary sutures and the mandibular condyles can further influence the development of vertical malocclusion. In addition, functional factors also modify the developing occlusion and can play a significant role in the development of malocclusion in the vertical plane.<sup>1</sup>

The purpose of this article is, first, to discuss the role of facial growth as an etiological factor in the development of vertical malocclusions and second, to discuss the possible association between functional factors and these malocclusions. A third purpose is to discuss certain diag-

nostic considerations and treatment aspects of special concern in the correction of these malocclusions.

## Development of vertical malocclusions

Vertical malocclusions can be divided into those that are dentoalveolar in origin and those that are predominantly skeletal due to the growth patterns of the jaws. Figure 1A and B illustrates a patient with a so-called skeletal deep bite; the patient has the characteristic concave facial profile with a reduction of anterior face height. The headfilm shows a Class II, division 2 malocclusion, which in part is due to a retrognathic mandible. In contrast, Figure 1C and D shows a patient with a skeletal open bite where the facial profile is convex with a pronounced retrognathic mandible. This patient, however, has a Class I malocclusion with a slightly increased overjet. The open bite and overjet are moderate in spite of a severe sagittal and vertical jaw discrepancy. In both examples the malocclusions are primarily the result of the

### Abstract

Vertical malocclusions develop as a result of the interaction of many different etiological factors; one of the most important of these factors is mandibular growth. Variations in growth intensity, function of the soft tissues and the jaw musculature as well as the individual dentoalveolar development further influence the evolution of these malocclusions. This article reviews the most common etiological factors and their possible contribution to the development of vertical malocclusions with special emphasis on the role of mandibular growth in the development of open bite and deep bite. The role of the cephalometric morphological analysis in the differential diagnosis of vertical malocclusion is emphasized. Aspects of orthodontic treatment of vertical malocclusions are illustrated with individual cases.

This manuscript was submitted October 1990. It was revised and accepted for publication March 1991.

### Key Words

Vertical malocclusions • Etiology • Development • Analysis • Diagnosis • Aspects of treatment

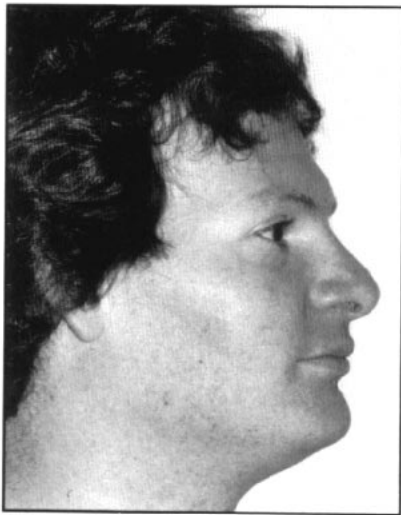

Figure 1A

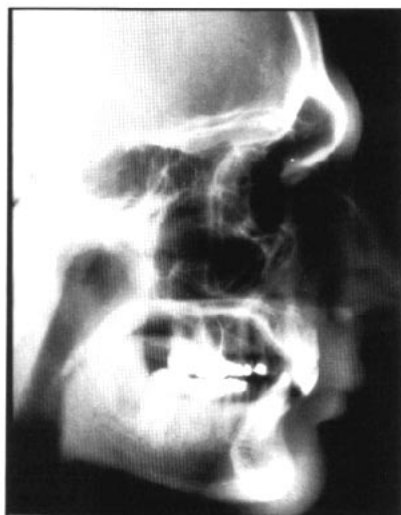

Figure 1B

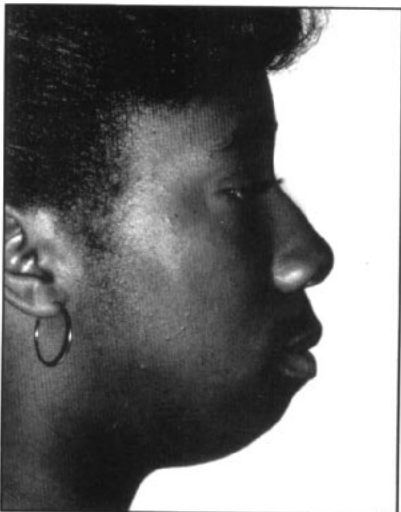


Figure 1C

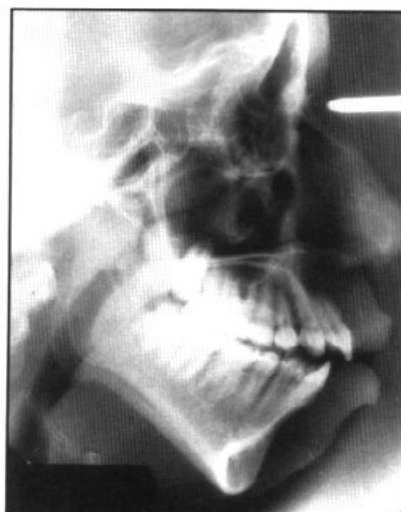

Figure 1D

**Figure 1A-B**  
Facial photo and lateral headfilm of 32-year-old male patient with extreme skeletal deep bite. The patient has a concave profile with a reduced anterior face height. The lateral headfilm, taken in centric relation, shows that the deep bite is skeletal and due to a retrognathic mandible with insufficient dentoalveolar compensation.

**Figure 1C-D**  
Facial photo and lateral headfilm of a 14-year-old female patient with a convex profile and an increased anterior face height. The lateral headfilm shows an extreme increase in the anterior face height with a mild open bite. Mandibular dentoalveolar growth has almost fully compensated for the increased vertical jaw relationship.

previous growth pattern of the face, the role of which will be discussed in greater detail, although the eruption of the teeth modified by functional factors has also greatly contributed to the final malocclusion.

#### Mandibular growth and vertical malocclusion

In studies of facial growth using the metallic implant technique, Björk<sup>2-6</sup> and Björk and Skjeller<sup>7,8</sup> demonstrated that the direction of growth of the lower jaw varies greatly in the normal population. Although the most common direc-

tion of condylar growth is vertical, with some anterior component, a more extreme upward, forward growth pattern of the condyle is not uncommon. Posterior growth is less frequently observed.

Patients with upward and forward growth of the mandibular condyle often have reduced anterior face height; if they develop a malocclusion, it is nearly always characterized by a deep bite. The direction of mandibular growth, as expressed at the chin, is mostly vertical. Growth in this direction often results in more horizontal displacement of the mandible and is most effective in improving the position of the chin, often desirable in patients with a Class II, division 1 skeletal malocclusion (Figure 2A and B). In more extreme cases of upward, forward growth of the condyle a Class II, division 2 malocclusion in combination with a skeletal deep bite, is common.

The erupting dentition in this type of mandibular growth characteristically undergoes a considerable amount of mesial migration of both the maxillary and mandibular teeth with some degree of proclination of the mandibular incisors (Figure 2A and B). Where the amount of mesial migration of the lower posterior teeth does not equal the advancement of the incisors by proclination, secondary crowding of the front teeth frequently develops.

Patients with the so-called "long face syndrome," and a pronounced increase in lower face height, in contrast have a more posteriorly directed growth pattern of the mandibular condyle. The direction of mandibular growth, as expressed at the chin, is mostly vertical. The malocclusion most commonly observed in this type of patient is an anterior open bite often in combination with a Class I or II malocclusion. These patients usually have little or no improvement in horizontal mandibular position over time (Figure 3A and B). The associated dental eruption pattern of the posterior teeth is generally vertical and in some instances the anterior teeth may even become more retroclined with time. Late crowding is not an uncommon finding in this pattern of growth.

#### Growth rotations and vertical malocclusion

The changes related to facial growth illustrated with these two extreme growth patterns are due not only to differences in condylar growth direction, but are also the result of differences in anterior facial height (AFH) and posterior facial height (PFH) development.<sup>9</sup> These differences in height development lead to rotational growth or positional changes of the mandible that greatly influence the position of the chin. The factors that determine the increase

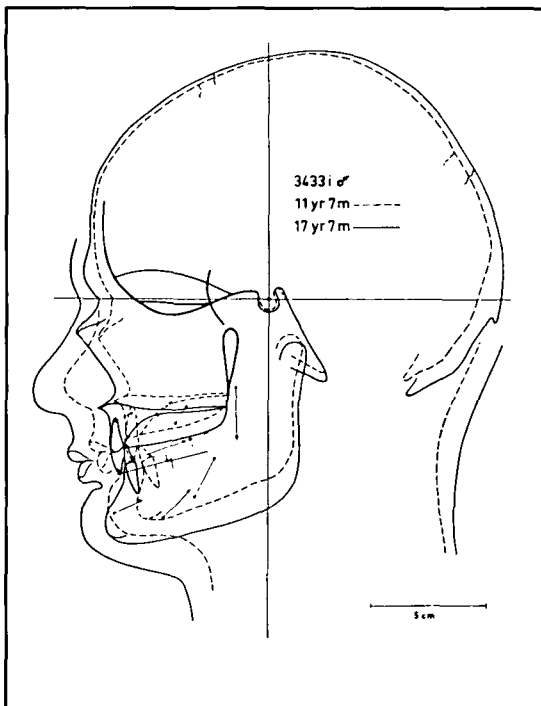


Figure 2A

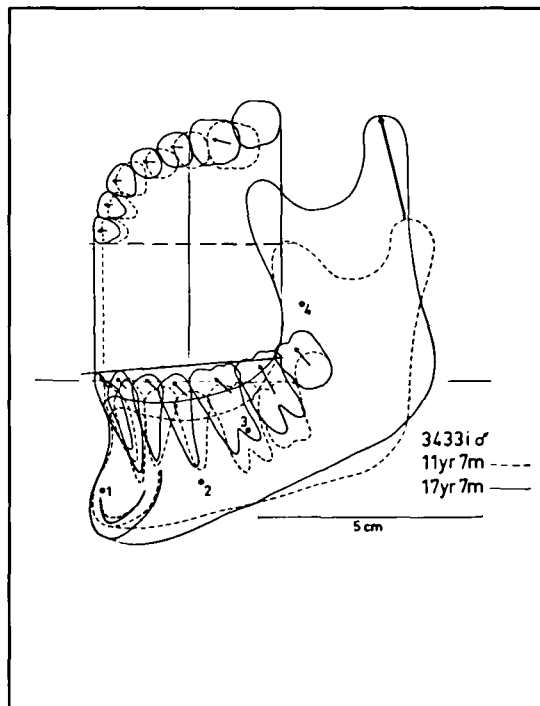


Figure 2B

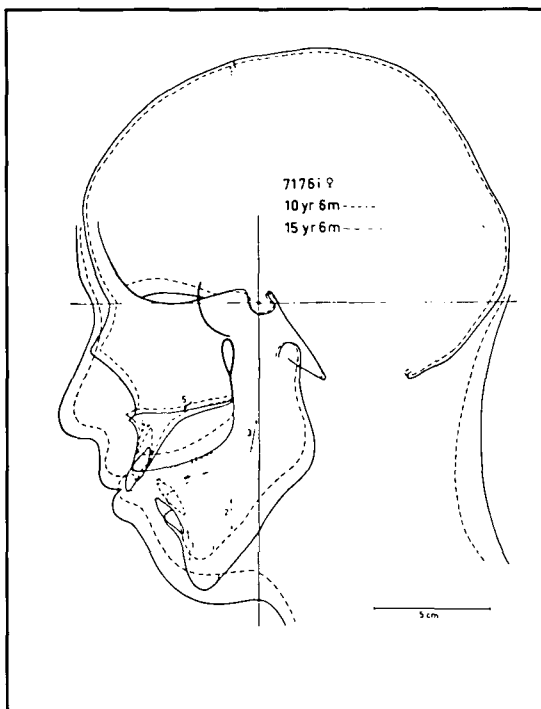


Figure 3A

in AFH are the eruption of the maxillary and mandibular posterior teeth and the amount of sutural lowering of the maxilla. PFH, on the other hand, is determined by the lowering of the temporomandibular fossae and condylar growth.<sup>9,10</sup> When vertical condylar growth exceeds dentoalveolar growth, i.e. eruption of the teeth in the jaws, forward rotation of the mandible occurs. In contrast, if dentoalveolar growth is greater than vertical condylar growth, the resulting change in mandibular position is back-

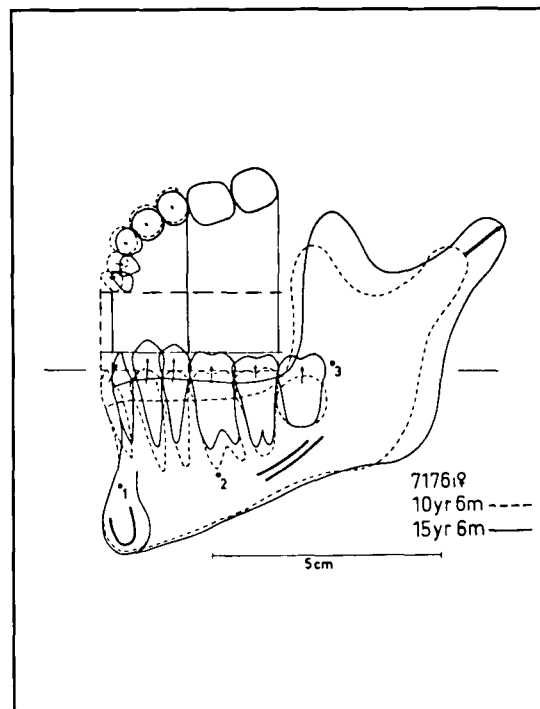


Figure 3B

ward or posterior rotation of the mandible. The two extreme mandibular growth patterns also show differences with respect to the amount of effective vertical condylar growth. Patients with an anterior condylar growth pattern usually have a greater amount of vertical growth than patients with posteriorly directed growth, a factor that further accentuates the differences.

The potential for anterior growth rotation can, in some instances and during certain active growth periods, be very pronounced. The risk

**Figure 2A**  
Case 3433 i. Characteristic facial growth pattern in a subject with skeletal deep bite. Lines connecting the implants in the maxilla and mandible indicate the direction of displacement of the implants between 11 years 7 months and 17 yrs 7 mos. Note the pronounced anterior or forward rotation of both the maxilla and mandible. No change in anterior occlusion occurred during this period. (From Bjork 1963)

**Figure 2B**  
Mandibular growth in Case 3433 i. This subject shows superior and anterior growth of the condyle with pronounced mesial eruption of the mandibular teeth. Note the extensive remodeling of the lower border, which masks about 50% of the actual rotation, seen in Figure 2A.

**Figure 3A**  
Case 7176 i. Subject with a characteristic vertical growth facial growth pattern. The differences in displacement of implants indicate that the mandible rotated posteriorly or backward during growth.

**Figure 3B**  
Mandibular growth and dentoalveolar development in Case 7176 i. The condylar growth direction is mainly posterior. The direction of the eruption of the teeth is almost vertical. Note that the mandibular incisors are erupting posteriorly, resulting in increased crowding in the mandible with time. (From Bjork, 1963)

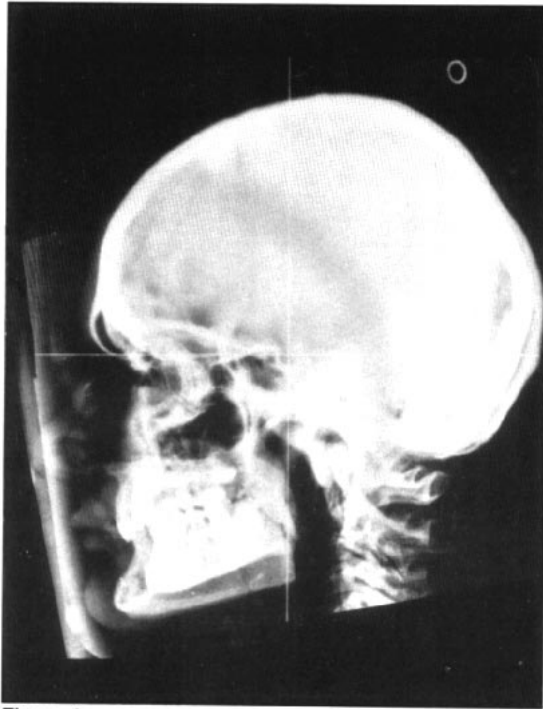


Figure 4

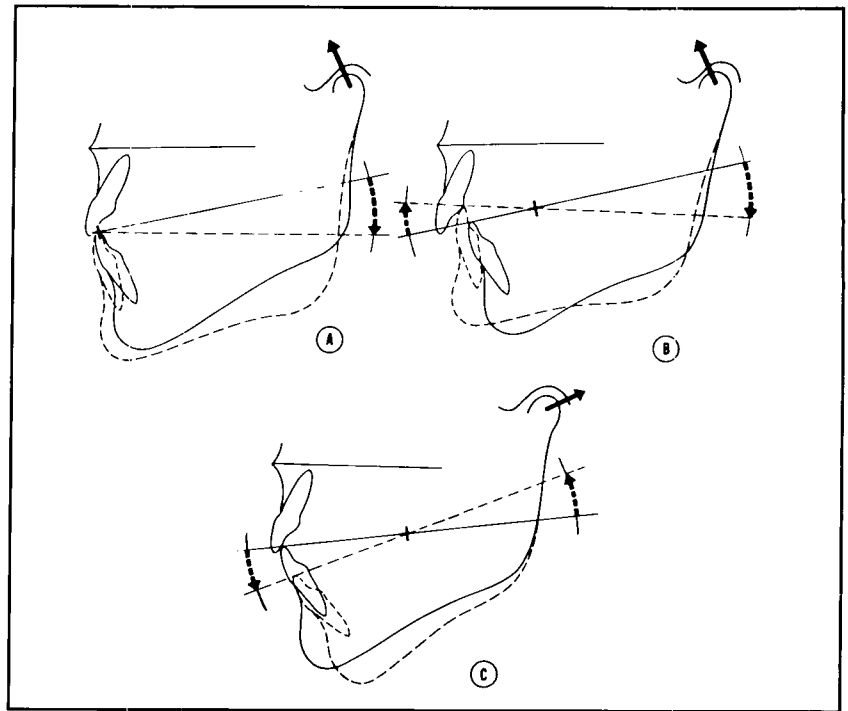


Figure 5

**Figure 4**  
General facial growth in Case 3433 i. The chin has become more prominent over time although limited increase occurred in anterior facial height. The rotation of the mandible as measured by change in the inclination of the lower border of the mandible was 7°. When measured to the implants the mandible rotated about 15° during this growth period.

**Figure 5A-C**  
Schematic illustration of mandibular growth rotations. A. Anterior rotation with the fulcrum point located at the incisors, as observed in patients with a stable occlusion. B. In patients with lack of anterior occlusion the fulcrum point is located further back along the occlusal plane. C. When posterior rotation takes place the fulcrum point is located near the mandibular condyles. (From Björk, 1969)

of developing a deep bite during these growth periods is particularly increased. Whether or not a deep bite develops depends on the relationship between the maxillary and mandibular incisors. If the mandibular incisors have proper contact with the lingual surfaces of the maxillary incisors chances are best that a deep bite will not develop. Björk<sup>6</sup> demonstrated that under ideal circumstances the fulcruming point for anterior or forward mandibular growth rotation is located at the incisors. If, however, proper incisal contact is lacking, either as a result of lip dysfunction or a fingersucking habit or if a severe sagittal skeletal jaw discrepancy exists, the patient will often develop a skeletal deep bite as a result of the growth pattern (Figure 4). The fulcruming point in these instances is located further back along the occlusal plane. Such growth related skeletal deep bites often develop early, remain fairly unchanged during the juvenile growth period and then continue to deepen during the pubertal growth spurt when growth intensity is at its greatest. Whereas the genetically determined mandibular growth pattern in general cannot be influenced by treatment, the occlusal relationships can be influenced by the orthodontist. The treatment goal should be to prevent further development of such severe growth related malocclusions by early intervention.

Patients with posterior condylar growth often have similar amounts of AFH and PFH increase, where the mandible translates during growth without rotation. However, in instances where

the increase in AFH is greater than in PFH, the mandible rotates posteriorly as illustrated in Figure 3A. This posterior growth rotation may result in an anterior open bite, depending on the extent of vertical dentoalveolar compensation. When treated orthodontically these patients are at increased risk for further mechanically induced posterior rotation by acceleration of their molar eruption and require careful control. The increased risk of extrusion in these patients is associated with their weaker masticatory musculature making vertical control an important consideration.<sup>11</sup>

#### Clinical significance of growth rotations

The clinical significance of growth rotations is their association with the development of skeletal open and deep bites. The growth rotation seen in Figure 5A is an example of anterior or forward rotation where the fulcruming point is located at the incisors. In patients where the incisor occlusion is stable and the overbite remains unchanged during the growth period the fulcruming point is located at the front teeth. If the incisor occlusion is unstable, the fulcruming point is located further back along the occlusal plane as seen in Figure 5B. In this situation the bite normally becomes increasingly deep over time as the result of greater posterior face height increase in combination with lack of anterior tooth contact. This deterioration of the occlusion is most pronounced during puberty when growth intensity is at its greatest, but continues throughout the growth period. Patients with a

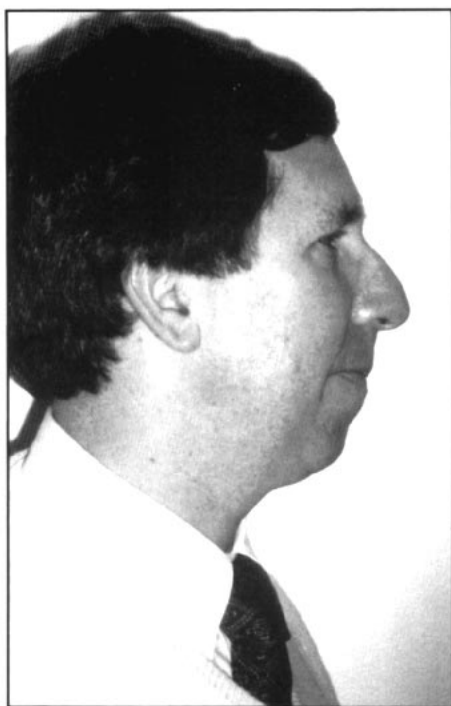

Figure 6A

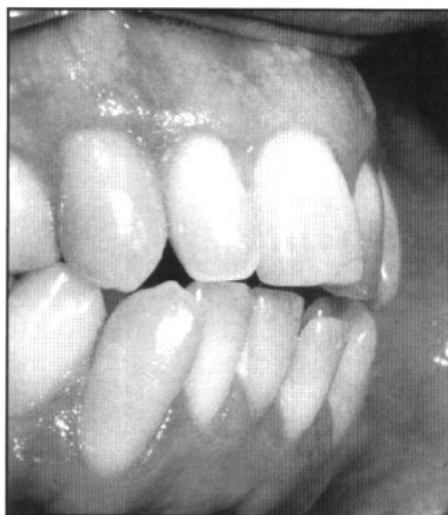


Figure 6B

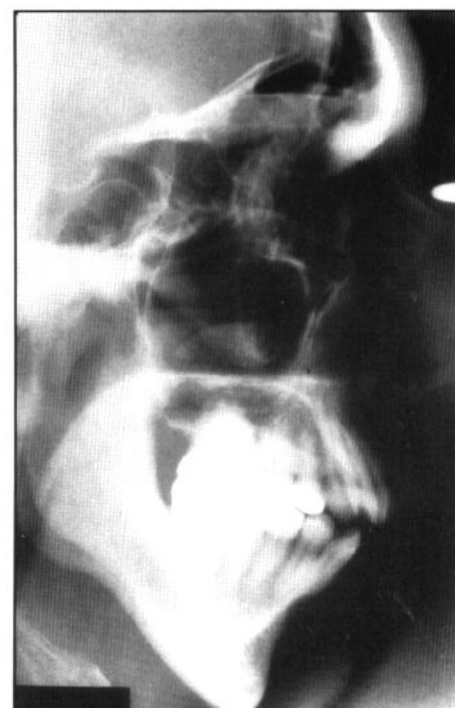

Figure 6C

pronounced tendency to anterior growth rotation and a deep bite should therefore be treated early and the occlusion supported throughout the growth period. Retention, especially in the mandibular arch, must also be maintained until mandibular growth is completed.

In the patient with vertical growth and posterior rotation of the mandible, the center for the growth rotation is located near the mandibular condyles as seen in Figure 5C. In this type of growth pattern early interception is also needed in order to maximize the dentoalveolar compensation. However, when more comprehensive treatment with full fixed appliances is indicated the situation is almost reversed, particularly if extractions are necessary. In those cases treatment should be postponed until after puberty, or at least until the potential for backward or posterior rotation is reduced. The reason for late treatment is that the tendency to extrude the posterior teeth decreases when there is less active growth. Space requirements are also easier to determine when the natural tooth movements, i.e. mesial migration and uprighting of the anterior teeth, are minimal.

Growth rotations of the jaws are normally not detectable by conventional superimpositions of serial headfilms on cranial base structures, but require individual superimpositions on stable structures in the mandible or maxilla, respectively. The actual rotation or *total rotation* in humans is generally masked on average by 50% modeling within the jaws. In a recent study of non-human primates, it was found that this

modeling or *intramatrix rotation* in the Rhesus monkey masked the rotations by about 75% in the maxilla and 90% in the mandible.<sup>12</sup> This surface modeling causes, in most instances, the lower border of the mandible to appear almost unchanged in its inclination to the cranial base and has led to misinterpretations of the actual growth changes and tooth movements in humans. An example of this is seen in Figure 4 where the change in mandibular lower border inclination over time, the so-called *matrix rotation*, was  $-7.3^\circ$  whereas the actual, or true rotation, was as much as  $-16.4^\circ$  anteriorly.<sup>8</sup>

Variation in growth intensity is an additional factor that not only induces change in the developing occlusion, but also affects the length and outcome of orthodontic treatment. During periods of low condylar growth intensity, such as the juvenile period or the prepubertal growth minimum, intensity may be as little as 1 to 2 mm per year in the condyles. Orthodontic treatment during these periods presents the orthodontist with significant clinical problems. It is difficult during these periods in some patients to obtain sufficient skeletal change and treatment can become protracted. The occlusal changes that are obtained are often primarily dentoalveolar, while needed skeletal correction is not fully achieved. Fortunately, some young patients are more actively growing during the juvenile period and skeletal correction can be achieved over a more reasonable period of time. Because the intensity of this growth is unpredictable, however, and it is difficult to determine the individ-

**Figure 6A-C**  
A, B and C. Patient with convex profile and pronounced increase in lower face height. The occlusion is Class I with excellent dentoalveolar compensation despite severely increased vertical jaw relationship.

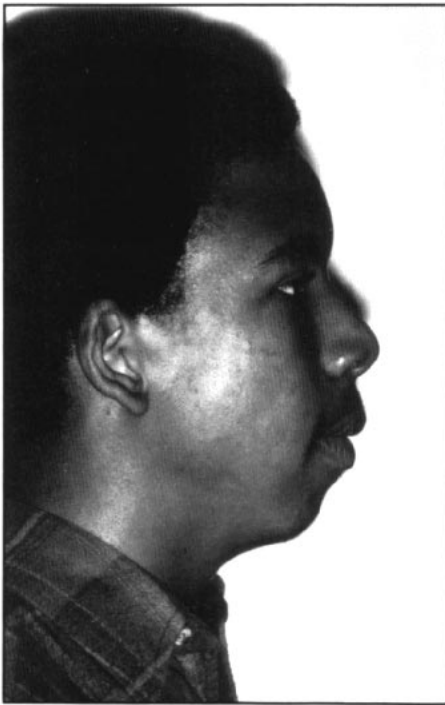

Figure 7A

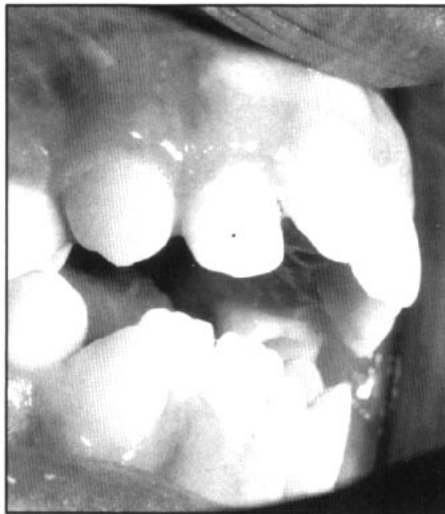

Figure 7B

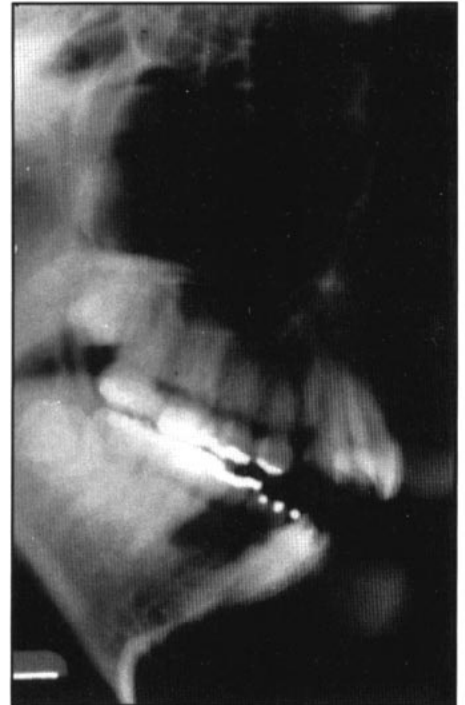

Figure 7C

**Figure 7A-C**  
**A, B and C. Patient with increased anterior face height and convex profile similar to the patient seen in Figure 6. The occlusion is again Class I but in contrast, this patient has a severe anterior skeletal open bite due to dysplastic development and no dentoalveolar compensation.**

ual growth potential, interceptive or early treatment can sometimes be extended and therefore, impractical.

#### Facial morphology, muscle function and vertical malocclusion

In a study of the facial morphology in three groups of subjects, low angle, average and high angle, Isaacson et al.<sup>13</sup> found that high angle and low angle subjects had similar upper face height development. Vertical height from the palatal plane to the maxillary molars, however, was significantly greater in the high angle cases than in the other two groups, indicating that posterior dental eruption generally is greater in high angle cases. Lower anterior face height was also found to be significantly greater in the high angle group than in the normal or the low angle groups. The difference in posterior dentoalveolar development in the maxilla is associated with weaker musculature in high angle cases as opposed to stronger musculature in the low angle cases as reported by Möller<sup>14</sup> and Ingerwall.<sup>15</sup> It has been hypothesized that the reason for the increased tendency to further bite opening in high angle cases during treatment is that high angle cases have significantly less bite force than low angle cases.<sup>16</sup> A recent study by Ingerwall, however, did not support this contention.<sup>17</sup> Differences in mandibular rest position between normal and high angle cases and patency of the airways have often been connected with the "long face syndrome." Airway problems, such as large adenoids, tonsils or blocked airways due to septum deviations, large concae, or allergies

are frequently observed in high angle cases and may affect mandibular posture allowing more freedom for posterior eruption. This hypothesis is supported by Linder-Aronson<sup>18,19</sup> who demonstrated closing of the mandibular plane angle and reduction in the anterior face height following removal of adenoids and tonsillectomy.

#### Cephalometric analysis of vertical malocclusion

In describing the facial morphology of a patient with a vertical malocclusion, orthodontists routinely measure the upper and lower face height as well as the vertical jaw relationship. This measurement of vertical jaw relationship is a relative measure of the difference in inclination between the maxilla represented by the palatal plane and the mandible represented by the mandibular plane. One important component, however, is often not included in the description, namely, the extent of dentoalveolar compensation in the maxilla and mandible.

Dentoalveolar compensation, first described by Björk<sup>4</sup> and later discussed by Solow<sup>20</sup> is, under favorable circumstances, *compensatory*, and masks even more severe skeletal discrepancies. In the ideal situation, this compensation masks discrepancies in all three planes of space. The dentoalveolar changes may, however, also be unfavorable or *dysplastic* and contribute to an occlusal problem more severe than that caused by the actual skeletal discrepancy. It is unfortunate that most cephalometric analyses do not directly measure the compensatory or dysplastic development. The following measurements will allow the determination of possible compensatory or dys-

plastic development within each of the jaws. In the maxilla, the *maxillary zone*, measured as the angle between the palatal plane (ANS-PNS) and the maxillary occlusal plane (mean  $10^{\circ} \pm 3^{\circ}$ ), describes the extent of compensatory or dysplastic development. In the mandible, the *mandibular zone*, measured between the mandibular plane (GO-GN) and the mandibular occlusal plane (mean  $20^{\circ} \pm 4^{\circ}$ ), similarly describes possible compensation.<sup>21</sup> If one or both of these measurements are increased in a patient with an increased vertical jaw relation, favorable dentoalveolar compensation is indicated. On the other hand, if these measurements are normal or reduced in the same patient, either no compensation or dysplastic development has taken place. It is important not only for the diagnosis of a case, but also for the treatment plan, to determine if a deep or open bite is dentoalveolar or skeletal in nature. It is equally important to determine to what extent a dentoalveolar change has compensated for a skeletal deep or open bite as it may affect not only the treatment of choice but also the timing of treatment. Figure 6A-C demonstrates dentoalveolar compensation in a patient with a pronounced increase in vertical jaw relation primarily due to posterior inclination of the mandible of  $52^{\circ}$ , where the vertical compensation is almost complete. In contrast, the patient seen in Figure 7A, B, C, has a similarly severe skeletal problem and shows little or no compensation.

### Growth prediction (structural)

The traditional cephalometric morphological assessment of the lateral headfilm of a patient provides a general description of the patient's face. It gives the clinician an idea of how each of the facial components contributes to the patient's malocclusion. Conventional morphological analyses, however, give little or no information as the future growth pattern of the patient — information which is of great importance in the treatment planning as it affects not only the timing of treatment but also the choice of treatment mechanics. The structural criteria for prediction of mandibular growth rotations described by Björk,<sup>6</sup> can be clinically very helpful in the more extreme cases. Björk<sup>6</sup> suggested that the morphology and inclination of the mandibular symphysis, the shape of the lower border of the mandible, the thickness of the cortical bone below the symphysis and the anterior border of the mandible are useful and important indicators of future growth rotation, particularly in more extreme cases.

In their study of untreated subjects with metallic implants, Björk and Skieller<sup>7</sup> demonstrated

that the majority of patients rotate in a forward direction (anterior) and that it is more unusual to find patients who exhibit posterior growth rotation. They also showed that the mandibular plane angle, as such, is not a reliable indication of posterior rotation potential as several untreated subjects showed anterior rotation in spite of a high mandibular plane angle. This is of particular interest as orthodontists often base their predictions of future growth rotation on the inclination of the mandible. It does not deny that high angle cases generally may be more prone to mechanical extrusion of posterior teeth during orthodontic treatment, primarily because the high mandibular plane angle is associated with less muscle strength.<sup>16,17</sup>

In order to illustrate the above principles and their application in a clinical context, the following two cases are described.

### Aspects of treatment

#### Case MH, 8 years 1 month, Female

This patient had a Class I malocclusion with an anterior skeletal open bite due to a previous fingersucking habit. Her facial profile was convex and the mandible appeared retrognathic (Figure 8A-D). In addition to her fingersucking habit she had also developed a speech problem and had difficulty with the pronunciation of 'S' and 'T' sounds as well as a moderate lisp. Her mother insisted on having the malocclusion treated as the speech problems were resulting in problems at school. The cephalometric analysis showed an increased sagittal jaw relation of  $5.5^{\circ}$  and a mandibular plane angle of  $41^{\circ}$  with an increased anterior face height. The airways seemed adequate and there was no history of airway problems. Judging from the headfilm tracing at 8 years 1 month, the structural criteria of the mandible indicated a future growth potential associated with posterior rotation (Figure 9). It was therefore decided to treat the anterior open bite as conservatively as possible in an attempt to eliminate the open bite by limited interceptive treatment.

To minimize the potential for posterior rotation, the posterior teeth were not included in the appliance. Instead of the traditional lingual arch with spurs, only the maxillary central incisors were fitted with bands provided with tongue spurs that reached down below the incisal edges of the mandibular incisors.<sup>22</sup> In addition, the patient was instructed to chew sugarless gum for a minimum of 2 hours per day to encourage masticatory muscle activity in the hope that this would reduce the potential for further bite opening. In the mandibular arch a passive lingual arch was placed to maintain arch



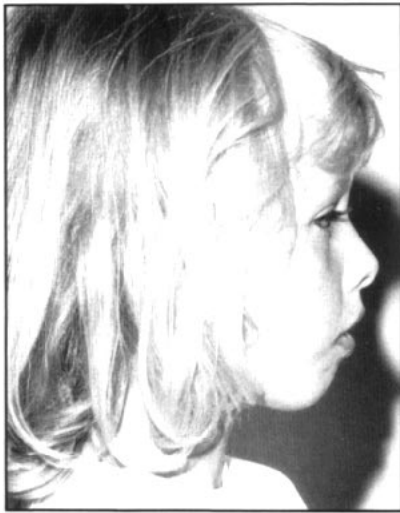

Figure 8A

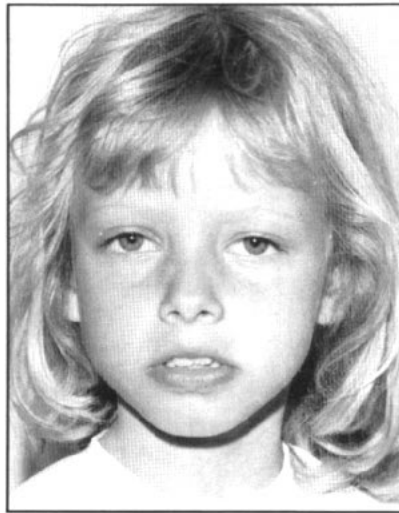

Figure 8B

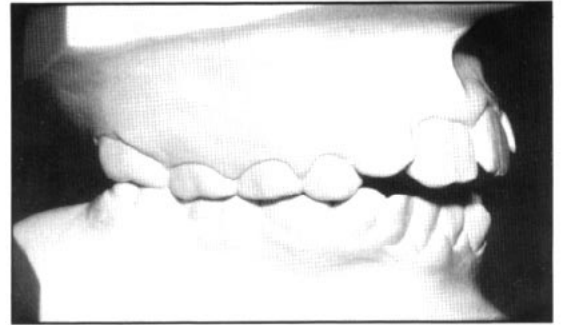


Figure 8C

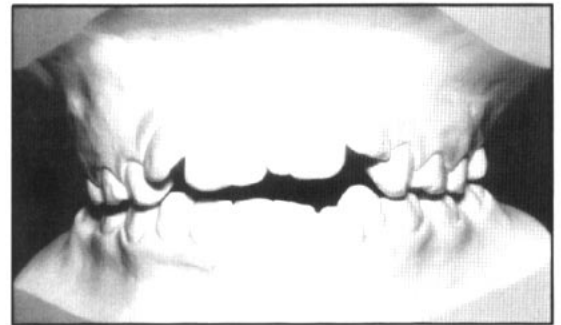


Figure 8D

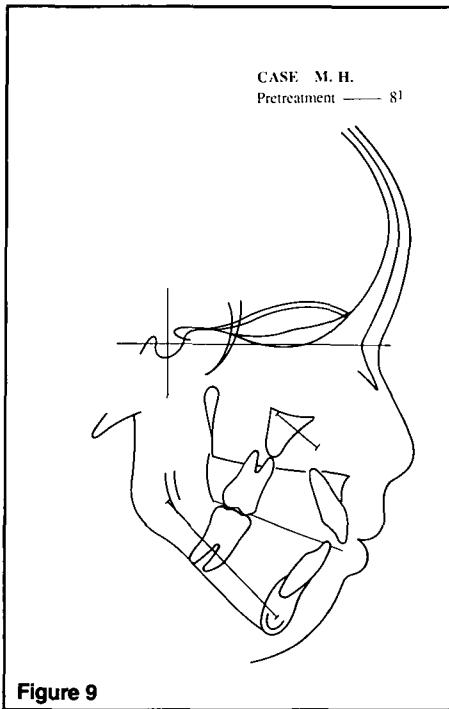


Figure 9

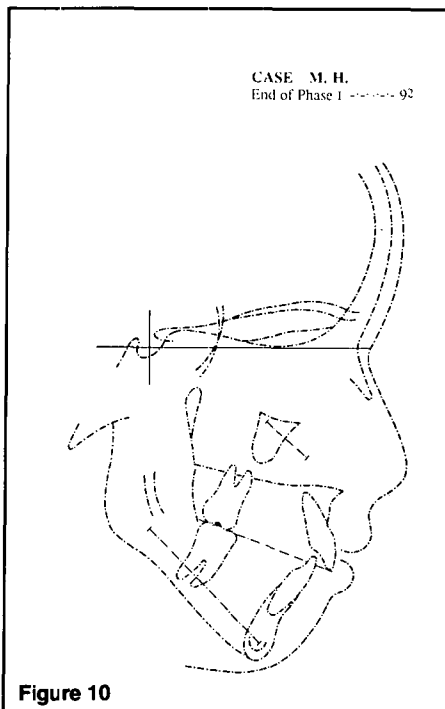


Figure 10

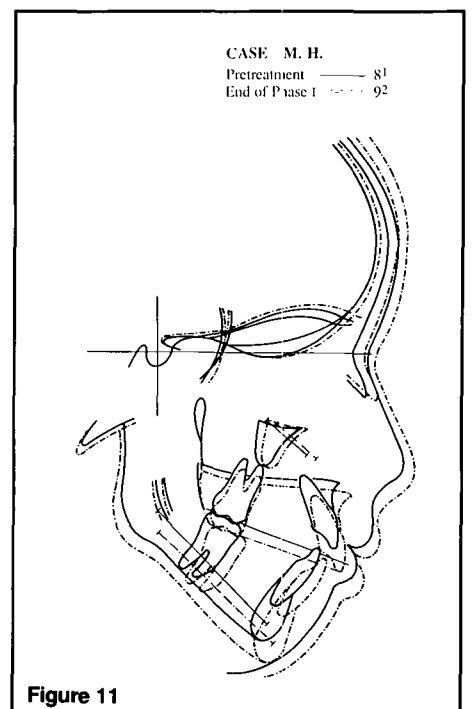


Figure 11

**Figure 8A-B**  
 Facial photo of Case MH. Female age 8 yrs 1 mo. The anterior face height is increased and the patient has a convex profile with a retrognathic chin. Lip closure is incompetent.

**Figure 8C-D**  
 Study casts of case MH show a Class I malocclusion with an anterior open bite and moderate crowding.

**Figure 9**  
 Cephalometric tracing of case MH at 8 yrs 1 mo shows a skeletal open bite with proclination of both maxillary and mandibular anterior teeth. The

structural signs indicate potential for posterior rotation.

**Figure 10**  
 Cephalometric tracing of case MH at 9 yrs 2 mos shows normal overbite, Class I occlusion and increased overjet.

**Figure 11**  
 Growth and treatment analysis of Case MH. The general direction of facial growth was downward and forward with no increase in the sagittal or vertical jaw relationships. The appliance consisted of two bands on the maxillary central incisors with spurs to prevent fingersucking and tongue dys-



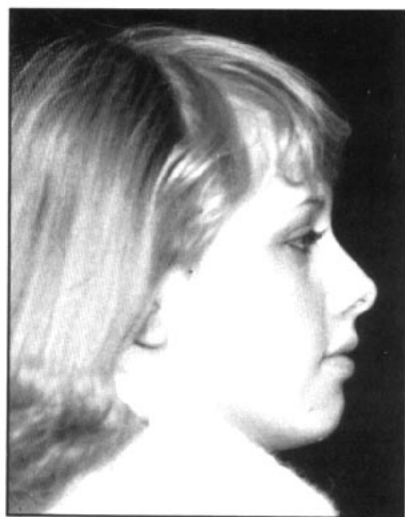

Figure 12A



Figure 12B

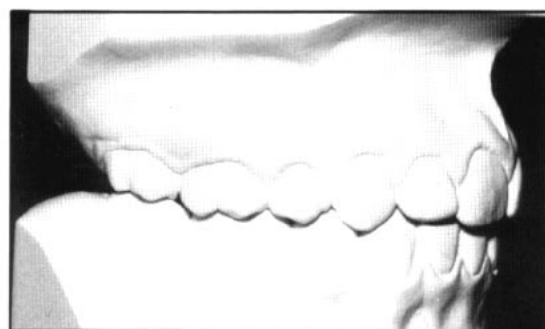


Figure 12C

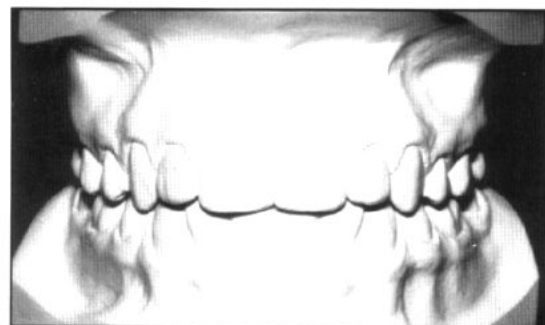

Figure 12D

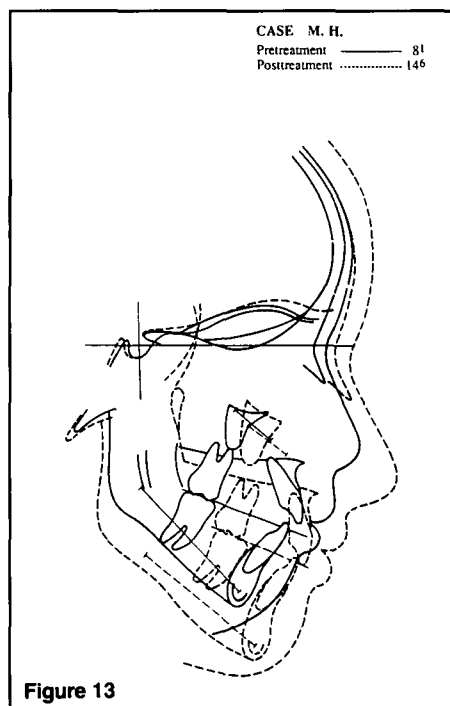


Figure 13

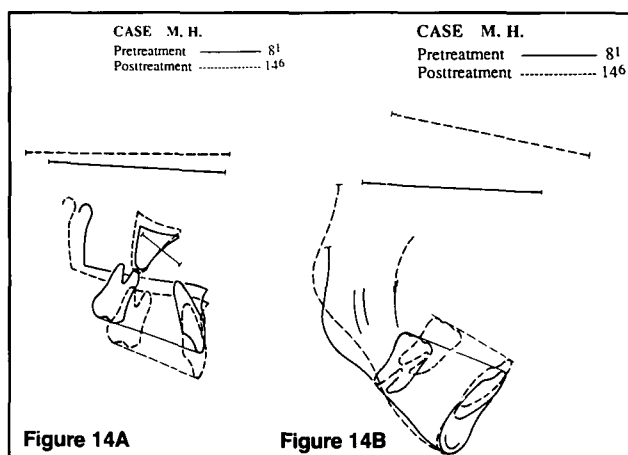


Figure 14A

Figure 14B

clusion posttreatment is now Class I with normal overjet and overbite.

**Figure 13**

Facial growth in Case MH from 8 yrs 1 mo to 14 yrs 6 mos was in a downward forward direction in both jaws. The sagittal jaw relation improved considerably during the second phase of treatment. The vertical jaw relation was well controlled and remained unchanged.

**Figure 14A-B**

Maxillary and mandibular superimposition in Case MH posttreatment. A. The maxilla rotated posteriorly during the growth period in part because of the use of high pull headgear during the second phase of treatment. A considerable amount of molar eruption could be tolerated because of sufficient mandibular growth. B. Mandibular superimposition shows that the patient experienced about 20 mm of condylar growth from 8 to 14 years of age. The mandible rotated in a forward (anterior) direction, contrary to the structural prediction, due to greater posterior (PFH) than anterior face height (AFH) increase.

function. The patient was instructed to chew sugarless gum for 2 hours daily to improve lip and tongue function. In the mandible a lingual arch was placed to maintain arch length during the transition of the dentition.

**Figure 12A-B**

Facial photos of Case MH at 14 yrs 6 mos. The facial photos after the second phase of treatment, from 12 to 14 yrs 6 mos which included extraction of four first premolars, show a harmonious profile. There is now adequate lip closure and a straight profile.

**Figure 12C-D**

Study casts of Case MH at 14 yrs 6 mos. The oc-

length during the loss of the deciduous teeth. At 9 years 2 months, after 1 year of treatment with the spurs (Figure 10), the patient shows a normal overbite with a slightly increased overjet. The superimposition after 13 months of treatment (Figure 11) shows that mandibular growth occurred in a downward and forward direction with a small amount of anterior rotation as indicated by the change in the inclination of the mandibular reference line. The maxilla followed the mandible and no change in the sagittal jaw relationship had taken place. The forward rotation of the mandible was contrary to what could be expected based on the morphological criteria, i.e. the inclination of the mandibular symphysis and the shape of the lower border of the mandible. It should be remembered, however, that in young patients such as this 8-year-old, these structural criteria are often not very pronounced and predictions can therefore be difficult. The patient should be given benefit of the doubt and treated conservatively.

At the end of the interceptive phase, the two bands with spurs were removed and the 9-year-old patient was told to come back in 6 months for a check of the lingual arch, which was maintained until all lower permanent teeth had erupted. No further treatment was initiated until 12 years of age when a new headfilm was taken and analyzed. The position of the mandibular incisors together with information from the headfilm indicated that in order to obtain a harmonious facial profile and occlusion, four premolars required extraction. Anchorage was established by means of a highpull headgear in combination with a transpalatal arch. This approach was used in an attempt to minimize the potential for maxillary molar extrusion during treatment.

The photos in Figure 12A-D show the patient's facial profile and occlusion at age 16, 2 years out of retention. The occlusion is good, she now has a harmonious soft tissue profile and the previous convexity has been reduced. Cephalometric growth and treatment analysis of the total growth period from 8 years 1 month to 14 years 6 months, after the two phases of treatment (Figure 13), show that her downward forward growth pattern had continued with pronounced forward rotation of the mandible. Detailed analysis of the changes within the maxilla and mandible (Figure 14A,B) show that the maxilla rotated slightly posteriorly whereas the mandible rotated anteriorly. A considerable amount of both condylar and sutural growth took place which permitted eruption of the molars and incisors.

This case is an example of two-phase treatment with early interception and later corrective treatment in a high angle case where an unfavorable growth pattern was anticipated. By careful application of mechanics and good treatment timing, undesirable side effects were avoided and forward growth of the mandible maximized. It may be argued that this patient had a functional open bite rather than a true skeletal open bite. Few clinicians, however, would disagree that this type of facial morphology often tends to open up during treatment and that these patients frequently finish with an undesirable profile.

#### **Case BK, 11 years 2 months, Female**

This patient had a skeletal deep bite with pronounced reduction of anterior facial height. She also had extreme retrognathism of the mandible as seen in her facial photos (Figure 15A-F). Her occlusion was so deep that she had marked imprints of her mandibular incisors in the palatal mucosa and she complained of occasional pain and bleeding in the area (Figure 15E). Lateral headfilm analysis showed an increased sagittal jaw relationship (ANB  $9^\circ \approx \text{mean } 3^\circ \pm 2.5^\circ$ ) due to a retrognathic mandible (Figure 16). The vertical jaw relationship was similarly reduced ( $2^\circ \approx \text{mean } 25^\circ \pm 6^\circ$ ) due to anterior inclination of the mandible ( $14^\circ \approx \text{mean } 33^\circ \pm 6^\circ$ ). This malocclusion was the result of extreme anterior rotation of the mandible in combination with a lack of incisor contact as illustrated in Figure 5B. Lack of an anterior fulcruming point, in combination with the growth pattern of the mandible, has caused the development of this extreme deep bite.

Early treatment of this patient could have prevented the development of this sagittal and vertical malocclusion. However, it should be recognized that this is an extreme case with an exceptional amount of upward and forward condylar growth. The total treatment time, therefore would have been protracted even if started early because of the marked sagittal discrepancy. The occlusion would have had to be stabilized during the entire growth period to prevent post-treatment relapse of the deep bite.

Because this patient lived in a remote area of the country without access to orthognathic surgery, the orthodontist decided to attempt non-surgical treatment. He hoped that facial growth and appropriate mechanics would correct the severe sagittal and vertical skeletal discrepancies. This clinician used Begg appliances routinely and tried for about a year to correct the deep bite with little success. At this time the

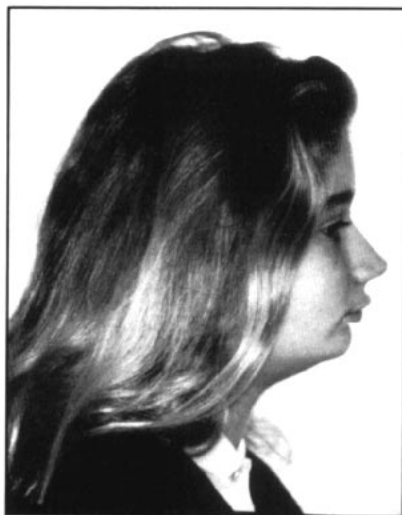


Figure 15A



Figure 15B

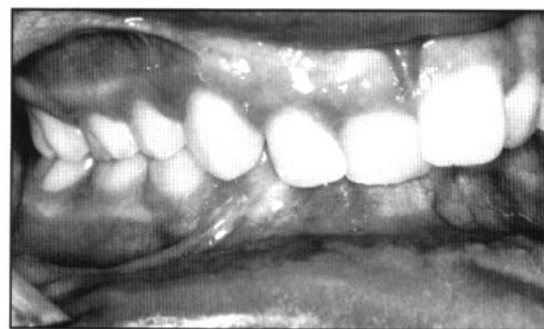

Figure 15C

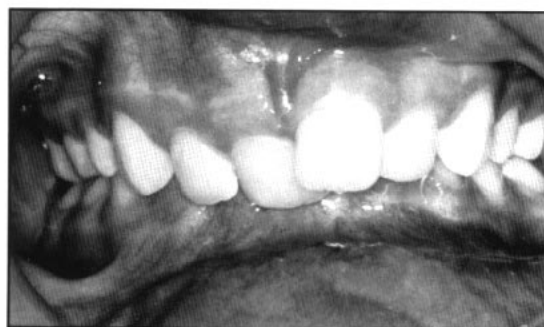

Figure 15D

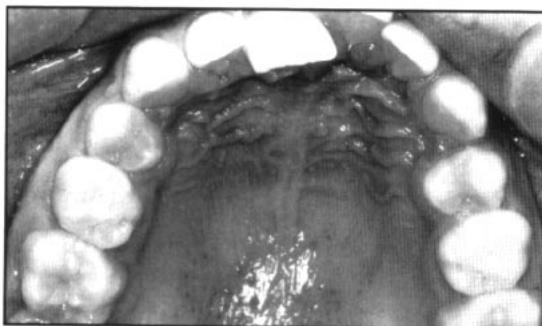

Figure 15E

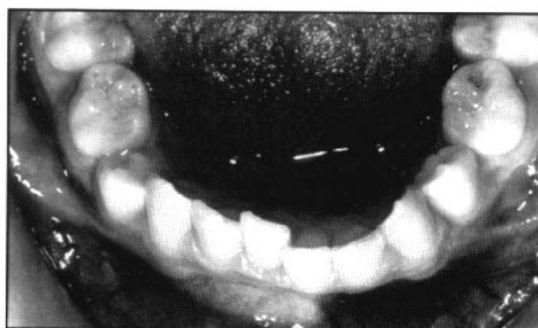

Figure 15F

**Figure 15A-B**  
Case BK. Female, 11 yrs 3 mos. Pretreatment facial photos show a severely reduced anterior face height and a retrognathic chin. The patient has a concave profile with a deep mentolabial sulcus.

**Figure 15C-F**  
Intraoral photos at age 11 yrs 3 mos of case BK show an extreme Class II division 2 malocclusion with a severe deep bite. The mandibular anterior teeth have created a groove in the palatal mucosa and the patient often has pain and bleeding from the area due to traumatic occlusion.

**Figure 16**  
The pretreatment headfilm tracing of case BK shows an extreme skeletal deep bite in combination with severe retrognathia of the mandible. The anterior facial height is severely reduced.

patient moved to an area where orthognathic surgery was available and transferred to another orthodontist (the author). The tracing of a cephalometric headfilm after 1 year 2 months of treatment (Figure 17) shows that the incisors and molars had been tipped back severely with no appreciable improvement in the occlusion. Cephalometric analysis of this treatment period (Figure 18) shows that the patient had grown vertically without any forward change of the mandible. A hand/wrist plate taken at this time showed that little additional growth could be expected as the patient already had closure of all the epiphyses in the hand ( $H_w$ ).

The treatment plan for this second phase of treatment, initiated at age 13 years 1 month, included aligning of all teeth, while maintaining the deep bite. Following orthodontic alignment the mandible was to be advanced surgically and rotated vertically to increase the anterior face height. The surgical procedure, with the use of rigid fixation to stabilize bony fragments, left the patient with an increased anterior face height

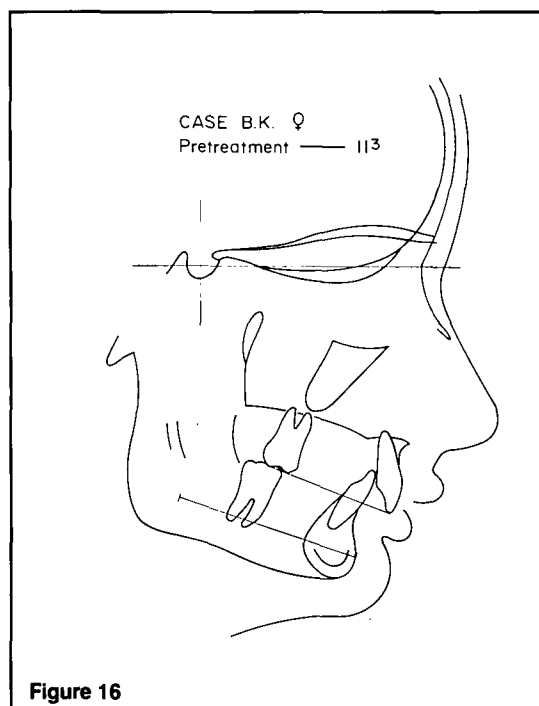


Figure 16

**Figure 17**  
Cephalometric tracing of Case BK at 12 yrs 5 mos following 1 yr 3 mos of non-extraction treatment with the Begg appliance. The deep bite has remained almost unchanged and there is no improvement in the sagittal relationship or the occlusion. Note the severe distal tipping of the maxillary and mandibular molars.

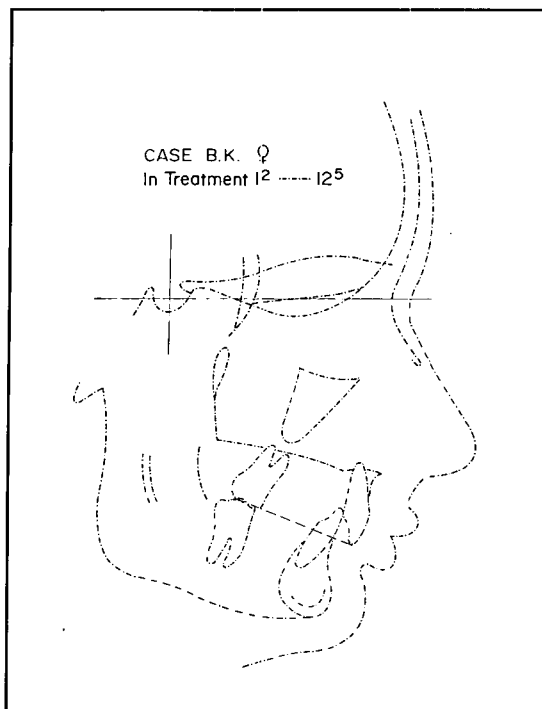


Figure 17

**Figure 18**  
General facial growth in Case BK after 1 yr 3 mos of treatment shows that the patient had primarily vertical growth during this treatment period. Considerable tipping of the maxillary and mandibular incisors took place in response to the use of Class II elastics.

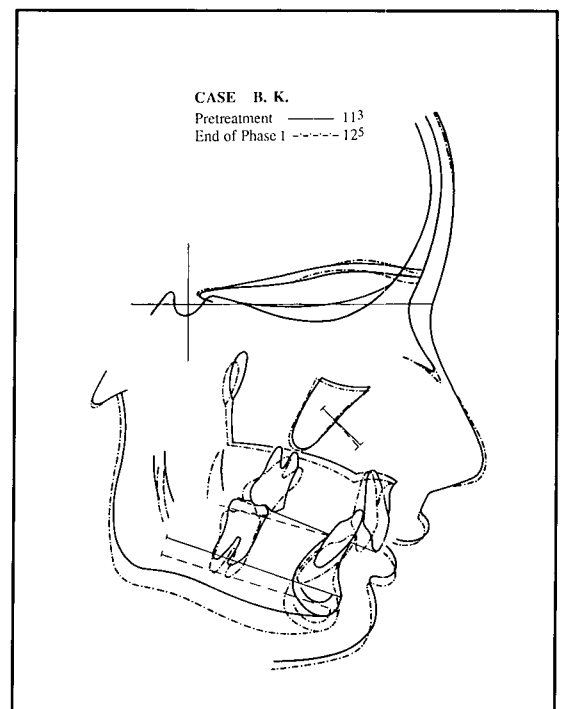


Figure 18

of 7 mm and full correction of the sagittal disharmony. Additional treatment of her occlusion was necessary to close the lateral open bite, often left after the horizontal and vertical correction in severe deep bite cases. After 3 months of orthodontic treatment the occlusion was corrected, appliances were removed and a gnathological positioner inserted for final detailing.

The posttreatment photos (Figure 19A-D) show great improvement in the patient's soft tissue profile. She now has a straighter profile with some improvement in lower anterior face height. The occlusion is Class I with normal overbite, overjet and good intercuspitation of all teeth. The lateral headfilm (Figure 20) shows the bony lag screws used to stabilize the mandible occlusion after treatment. Cephalometric growth and treatment analyses (Figure 21) show the mandibular advancement and lowering with considerable torque of the maxillary incisors necessary to obtain a good occlusion.

Posttreatment stability of these two cases is expected to be good as no further growth is anticipated. An excellent occlusion was obtained.

### Summary

To successfully treat vertical malocclusions, it is important for the clinician to have a good

understanding of the etiological factors that lead to development of these malocclusions. Growth processes associated with these malocclusions must be understood as well as normal and abnormal function of the soft tissues, i.e. the lips and tongue, in order to successfully diagnose and plan treatment for these patients.

In this article we have discussed the mechanism by which vertical malocclusions can develop and the influence function may have on vertical development. The roles of soft tissue and muscle dysfunction in the development of vertical malocclusions are still only vaguely understood. Their influence on the stability of the occlusion following treatment needs further investigation.

### Author Address

Ib Leth Nielsen, DDS  
Dept. of Growth and Development  
University of California  
San Francisco, CA 94143

*I.L. Nielsen is Clinical Professor in the Department of Growth and Development at the University of California, San Francisco.*

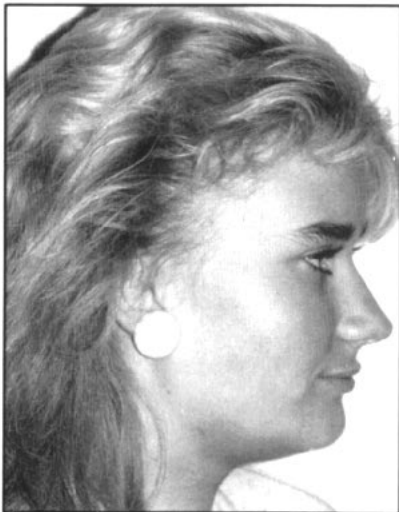


Figure 19A




Figure 19B

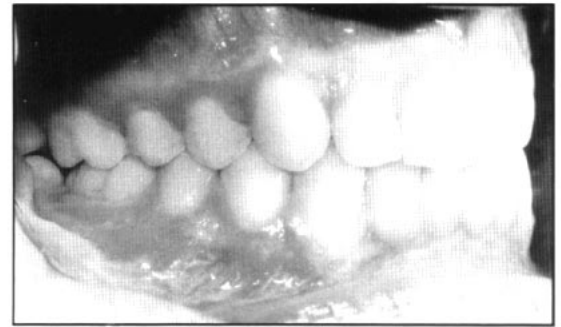


Figure 19C

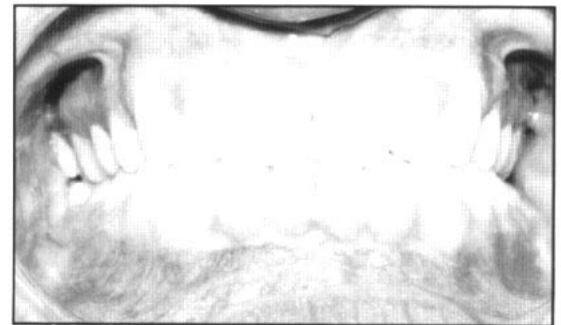


Figure 19D

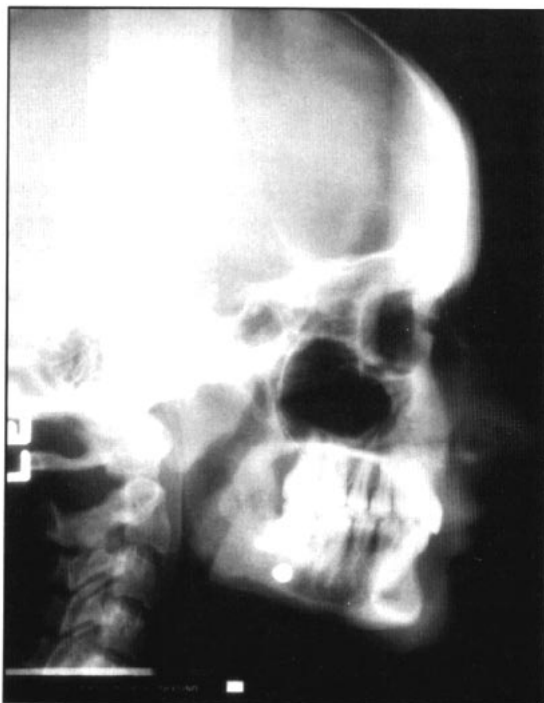

Figure 20

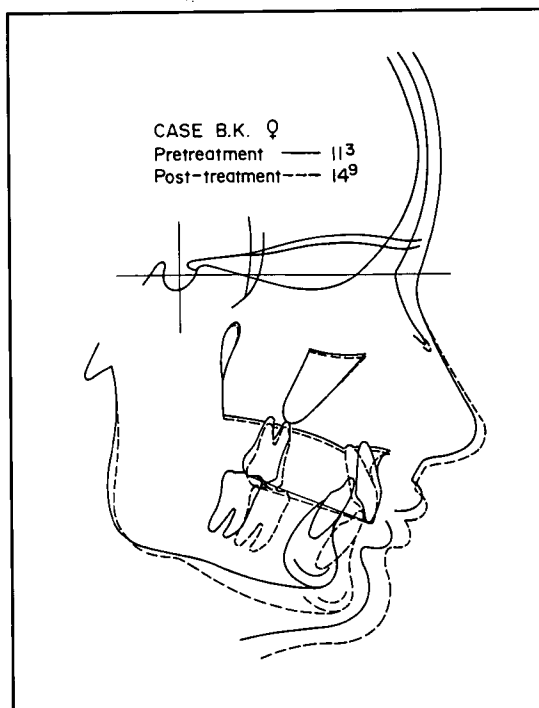


Figure 21

**Figure 19A-B**  
Facial photos of Case BK at 14 yrs 9 mos. Following orthodontic therapy and orthognathic surgical advancement of the mandible, the facial profile is now straight with an increase in the lower face height.

**Figure 19C-D**  
Intraoral photos of Case BK following treatment (by the author). The occlusion is now Class I with normal overjet, overbite with good intercuspidation of the teeth.

**Figure 20**  
Posttreatment lateral headfilm of Case BK at 14 yrs 9 mos. The profile is now harmonious and good interincisal relationships of the teeth have been obtained. Note the bony lag screws that eliminated the need for intermaxillary fixation.

**Figure 21**  
General facial growth from 11 yrs 3 mos to 14 yrs 9 mos in Case BK. The surgical advancement has increased the vertical face height and corrected the sagittal jaw discrepancy.

## References

1. Skieller V. Cephalometric analysis in the treatment of overbite. *Trans Eur Orthod Soc* 1967; 147-157.
2. Björk A. Facial growth in man, studied with the aid of metallic implants. *Acta Odontol Scand* 1955; 13:9-34.
3. Björk A. Variations in the growth pattern of the human mandible: longitudinal cephalometric study by the implant method. *J Dent Res* 1963; 400-411.
4. Björk A. Sutural growth of the upper face studied by the implant method. *Acta Odontol Scand* 1966; 24:109-129.
5. Björk A. The use of metallic implants in the study of facial growth in children: method and application. *Am J Phys Anthropol* 1968; 29:243-254.
6. Björk A. Prediction of mandibular growth rotation. *Am J Orthod* 1969; 55:585-599.
7. Björk A, Skieller V. Facial growth and development. An implant study at the age of puberty. *Am J Orthod* 1972; 48:61-74.
8. Björk A, Skieller V. Normal and abnormal growth of the mandible. A synthesis of longitudinal cephalometric implant studies over a period of 25 years. *Eur J Orthod* 1983; 5:1-46.
9. Isaacson RJ, Zapfel RJ, Worms FW, Erdman AG. Effects of rotational jaw growth on the occlusion and profile. *Am J Orthod* 1977; 72:276-286.
10. Stöckli PW, Teuscher U. Combined activator headgear orthopedics. In *Orthodontics, current principles and techniques* (ed. Graber TM, Swain BF). 1985, The C.V. Mosby Co. St. Louis.
11. Pearson LE. Vertical control in patients having backward-rotational growth tendencies. *Angle Orthod* 1978; 48:132-140.
12. Nielsen IL, Bravo LA, Miller AJ. Normal maxillary and mandibular growth and dentoalveolar development in *Macaca Mulatta*; A longitudinal cephalometric study from 2 to 5 years. *Am J Orthod Dentofacial Orthoped* 1989; 96:405-415.
13. Isaacson JR, Isaacson RJ, Speidel TM, Worms FW. Extreme variations in vertical facial growth and associated variations in skeletal and dental relations. *Angle Orthod* 1971; 41:219-229.
14. Möller E. The chewing apparatus. *Acta Physiol* 1966; 69:571-574.
15. Ingervall B, Thilander B. Relationship between facial morphology and activity of the masticatory muscles. *J Oral Rehab* 1974; 1:131-147.
16. Proffit WR, Fields HW, Nixon NL. Occlusal forces in normal and long-face adults. *J Dent Res* 1983; 62:566-570.
17. Ingervall B, Thüer U, Kuster R. Lack of correlation between mouthbreathing and bite force. *Eur J Orthod* 1989; 11:43-46.
18. Linder-Aronson S. Adenoids: their effect on mode of breathing and nasal airflow and their relationship to characteristics of the facial skeleton and dentition. *Acta Otolaryngol Scand (suppl.)*, 1970.
19. Linder-Aronson S. Effects of adenoidectomy on the dentition and facial skeleton over a period of five years. In: Cook JT, ed. *Transactions of the Third International Orthodontic Congress*. The C.V. Mosby Co. St. Louis, 1975.
20. Solow B. The dentoalveolar compensatory mechanism: background and clinical implications. *Brit J Orthod* 1980; 7:145-161.
21. Björk A. The relationship of the jaws to the cranium. In Lundström ed. *Introduction to orthodontics*. 1961; 104-140. McGraw-Hill, London.
22. Parker JH. The interception of the open bite in the early growth period. *Angle Orthod* 1971; 41: 24-44.